



## State of the Art Review

## Isolated meniscus injuries in skeletally immature children and adolescents: state of the art

Gustavo Vinagre<sup>1</sup>, Flávio Cruz<sup>2</sup>, Khalid Alkhelaifi<sup>3</sup>, Pieter D'Hooghe<sup>3,\*</sup><sup>1</sup> Department of Orthopaedic Surgery and Traumatology, Hospital de Verín, Verín, Galicia, Spain<sup>2</sup> Department of Orthopaedic Surgery, Universidade Federal do Estado do Rio de Janeiro, Rio de Janeiro, Brazil<sup>3</sup> Department of Orthopaedic Surgery, Aspetar Orthopaedic and Sports Medicine Hospital, Doha, Qatar

## ARTICLE INFO

## Keywords:

knee  
athletic injuries  
sports medicine  
meniscus  
arthroscopy

## ABSTRACT

The prevalence of isolated meniscal injuries in children and adolescents is low; however, we see an increase mainly due to intensified sports-related activities at an early age. A meniscal repair should be attempted whenever possible as children present with increased meniscal healing potential. The diagnosis and management of meniscal tears involve both patient factors and tear characteristics: size, anatomical location and associated injuries. Special attention should be given to the feature of discoid menisci and related tears as they require a specific management plan.

This state-of-the-art review highlights the most recent studies on clinical evaluation, surgical techniques, tips and tricks, pitfalls, outcomes, return-to-sports, geographical differences and future perspectives related to meniscal injuries in children and adolescents.

## Introduction

Meniscal injuries are less prevalent in children and adolescents than in adults. However, the increase in sports participation by the skeletally immature athlete has furthermore increased the incidence of meniscal injuries in this population. Those involve meniscal tears and symptomatic discoid meniscus.

The meniscus plays a fundamental role in shock absorption, load distribution, knee stability, joint lubrication and knee congruity. Meniscal deficiency is known to compromise the future of the knee, leading to premature, progressive osteoarthritis (OA)<sup>1,2</sup>

Surgical meniscectomy can lead to the development of early degenerative changes of the knee, ligamentous laxity and pain over time, especially when the procedure is performed at a young age stage.<sup>3–5</sup>

Numerous studies have stressed the importance of “meniscus retain, repair or replace” through a meniscal scaffold or meniscal allograft transplantation (MAT) to maintain knee joint homeostasis.<sup>6–8</sup> Whenever feasible, meniscus retention or repair is indicated to avoid the well-known deleterious effects of partial, subtotal, or total meniscectomy on the knee. Discoid lateral meniscus (DLM) is an abnormal congenital morphological anomaly of the knee characterised by a wide and thick meniscus that typically covers a larger area of the tibial plateau, and is

easily prone to damage as a result.<sup>9–14</sup> A symptomatic DLM is usually linked to a meniscal tear or an unstable discoid meniscus, and can be treated with partial meniscectomy, ‘normal reshaping’ of the discoid meniscus with meniscoplasty/saucerisation, removing the central part of the meniscus to restore its standard crescent shape and retaining up to 8 mm of peripheral rim, with or without meniscal repair.<sup>15</sup>

This state-of-the-art review aimed to provide an overview of the most important available evidence on meniscal injuries in children (below the age of puberty) and adolescents (the period from puberty to adulthood).

## Epidemiology

The true prevalence of isolated meniscal injuries among skeletally immature children and adolescents is still unknown. Initially, meniscal injuries in children were thought to be extremely rare, especially under 10 years of age, unless associated with a discoid meniscus.<sup>16</sup> Some authors suggest that the occurrence of an isolated meniscal injury is greater than previously thought, mainly due to increased sports participation at a younger age.<sup>12,13</sup> A study on 1082 meniscal injuries in high school athletes reported an overall meniscal injury rate of 5.1 per 100 000 athletes and a 40.7 per 100 000 incidence in boys’ football and 23.2 per 100 000 in girls’ soccer.<sup>17</sup> Stanitski *et al*<sup>18</sup> reported in their study that 70% of the

\* **Corresponding author.** Dr Pieter D'Hooghe, Department of Orthopaedic Surgery, Aspetar Qatar Orthopaedic and Sports Medicine Hospital, Doha, Qatar

E-mail address: [pieter.dhooghe@aspetar.com](mailto:pieter.dhooghe@aspetar.com) (P. D'Hooghe).

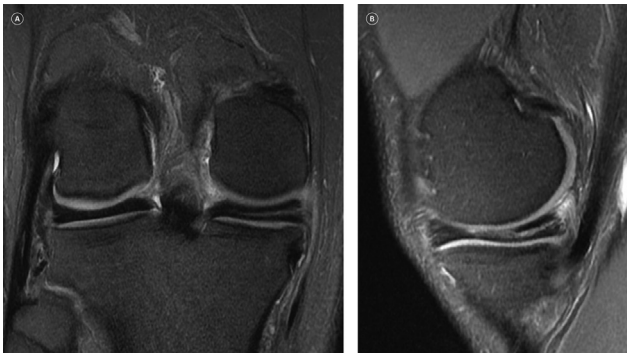
[@DrGVinagre](https://twitter.com/DrGVinagre) (G. Vinagre), [@kalkhelaifi](https://twitter.com/kalkhelaifi) (K. Alkhelaifi), [@PdHooghe](https://twitter.com/PdHooghe) (P. D'Hooghe)

<https://doi.org/10.1136/jisakos-2020-000496>

Received 6 July 2020; Received in revised form 28 November 2020; Accepted 22 December 2020

Available online 11 January 2022

2059-7754/© 2021 The Authors. Published by Elsevier Inc. on behalf of International Society of Arthroscopy, Knee Surgery and Orthopaedic Sports Medicine. This is an open access article under the CC BY license (<http://creativecommons.org/licenses/by/4.0/>).



**Fig. 1.** Right knee MRI—a rare case of an adult patient with an ipsilateral lateral and medial discoid meniscus. (A) Coronal view and (B) sagittal view: medial discoid meniscus horizontal tear.

47 meniscal injuries in adolescents and children involved the medial meniscus. According to Mitchell *et al*'s<sup>17</sup> study of 1082 meniscal injuries in high school athletes, anterior cruciate ligament (ACL) injury is highly associated with meniscal injuries in 36.9% of the cases.

The prevalence of meniscal tears in 124 skeletally immature patients who underwent ACL reconstructions was 69%, with the lateral meniscus being involved in the majority of cases.<sup>19</sup>

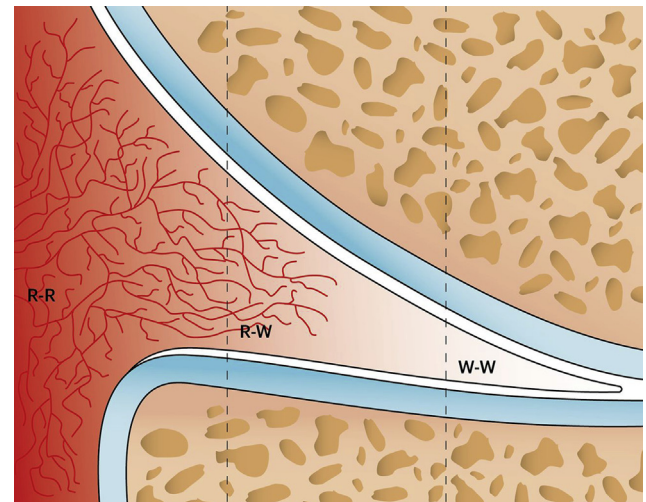
However, the prevalence of ACL-associated ramp lesions in children and adolescents is similar to that in adult populations (15%–24%)<sup>20</sup>.

Discoid lateral meniscus has a prevalence that ranges from 0.4% to 20%, with higher prevalence in Asian children.<sup>9–14 21 22</sup> The presence of a medial discoid meniscus is very rare: 0.07%–0.3% when compared with 1.2%–5.2% for the lateral discoid meniscus.<sup>14 23</sup> Even more rare is to have ipsilateral lateral and medial discoid meniscus (figure 1). The prevalence of bilateral DLM is unknown due to its asymptomatic nature.<sup>24</sup> The longitudinal type of tears accounts for 50%–90% of meniscal injuries in the young, while bucket-handle meniscal tears represent approximately 14% of all meniscal tears, mostly affecting the medial meniscus.<sup>24–27</sup> According to Shieh *et al*'s<sup>26</sup>, a retrospective study of 293 children and adolescents with meniscal tears who underwent arthroscopic surgery showed that patients with discoid tears had a lower mean age (12.7) than those with non-discoid tears (15.7).

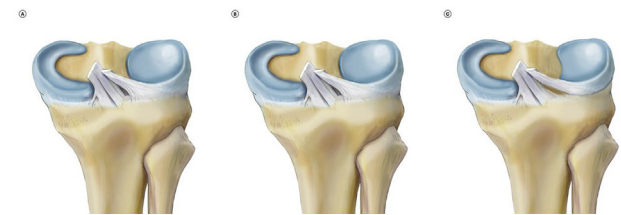
### Embryology and anatomy

The menisci arise from mesenchymal tissue within the limb bud and are formed in the knee joint between the 8th and 10th week of embryonic life, being evident by week 8 and having a normal appearance by week 14 of embryological development.<sup>28</sup> Blood supply arises from the periphery through the perimeniscal capillary plexus, being fully vascularised at birth, two-thirds peripheral by 9 months and then gradually decreases.<sup>21</sup> Adult morphology is reached by the age of 10 years. Commonly, the peripheral rim is known as the 'red-red' (R-R) zone and the inner one-third as the 'white-white' zone (figure 2). By adulthood, only the peripheral 10%–30% will receive blood supply. The inner two-thirds of the mature menisci receive nutrition by diffusion from the synovial fluid. Medial meniscus has a C-shape and covers approximately 50% of the medial tibial plateau while the lateral meniscus is more circular and covers approximately 70% of the lateral tibial plateau. The inner structure of the meniscus consists of mostly type I collagen fibres arranged in a circumferential pattern parallel to its long axis. Radial, oblique and vertically oriented fibres help the circumferential fibres to reduce the (hoop) stresses.<sup>29 30</sup>

A discoid meniscus is an abnormal congenital morphological anomaly: it is thicker, has less vascularity, has a 'disc' shape instead of a normal 'semilunar' shape and covers more tibial plateau. The histology and ultrastructure of the discoid meniscus are different from those of a normal meniscus. In the discoid meniscus, there are decreased collagen



**Fig. 2.** Schematic drawing of the meniscus vascularisation in three zones (coronal section). R-R, Red-Red; R-W, Red-White; W-W, White-White.



**Fig. 3.** Watanabe classification of discoid lateral meniscus: (A) type I: block-shaped stable, complete meniscus; (B) type II: block-shaped stable, partial meniscus; (C) type III: unstable meniscus, with stability arising only from the ligament of Wrisberg.

fibres and the presence of irregularly oriented collagen fibres. Intra-meniscal mucoid degeneration is common, and mucoid material has been found.<sup>31 32</sup>

The precise aetiology of a discoid meniscus is unknown, although some authors suggested that it is congenital, with a genetic or familial predisposition for the development of discoid menisci.<sup>14 33 34</sup>

According to Aydın Kabakçı *et al*'s<sup>35</sup> on human fetal cadavers, a fetal lateral meniscus classification was described, leading to a better understanding of the morphological development of fetal meniscal development.

The Watanabe classification describes three types of DLM based on their shape and tibial attachments (figure 3).<sup>36 37</sup>

### Mechanism of injury

Traumatic meniscus tears in children and adolescents have a clinical presentation similar to those in adults but are highly associated with ACL injuries.

Most of non-discoid meniscal injuries (80%–90%) occur during sports events. The mechanism of injury is a sudden twist of flexed knee with the foot planted during cutting and pivoting sports activities such as soccer, American football, basketball, skiing or wrestling.<sup>18 29 30 38–40</sup> We did not find any report describing a specific mechanism of injury for discoid meniscal tears, as the true natural history of discoid menisci is still thought to be unknown.<sup>41</sup>

### Risk factors and associated conditions

**Box 1** presents known risk factors and associated conditions related to meniscal injuries in children and adolescents.

**Box 1**

Risk factors and associated conditions of meniscus injuries in children and adolescents.

- Sports-related injuries: soccer, American football, basketball, skiing and wrestling.
- Higher injury rates during competition.
- Higher overall rate of youth sports participation, increased time and intensity and earlier single-sports participation.
- Higher body mass index, a greater varus mechanical axis angle, a higher Outerbridge grade cartilage status and a larger preoperative meniscal extrusion negatively impact postoperative outcomes.
- Anterior cruciate ligament (ACL) injury (acute: associated with lateral meniscus tear; chronic: posterior horn of the medial meniscus).
- Delayed reconstruction of an ACL-deficient knee.
- Asian children—higher prevalence of discoid meniscus.
- A discoid meniscus can be associated with knee abnormalities such as high fibular head, fibular muscular defects, hypoplasia of the lateral femoral condyle, osteochondritis dissecans of the lateral femoral condyle, hypoplasia of the lateral tibial spine and cupping of the lateral tibial plateau.

**Diagnosis***Clinical assessment and physical examination*

Young patient population with a meniscal injury present with activity-related pain, especially with twisting movements, as the predominant complaint. Additional symptoms, such as snapping, intermittent catching, locking or instability ('giving way' feeling) may be present and depend on the type of tear and injury characteristics. Further signs can be observed: quadriceps atrophy, flexed stance, swelling or haemarthrosis.

Although traumatic meniscal tears in children and adolescents present in a similar manner as in adults, they are more commonly associated with ACL tears, whether the ACL injury is acute or chronic. If there is suspicion of an ACL injury, meniscal injuries should be ruled out.

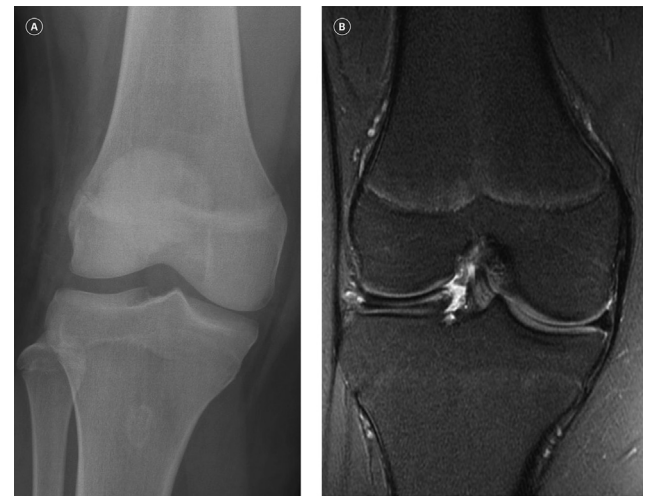
Findings on the physical examination of the patient include joint line tenderness, swelling, effusion and positive meniscus-specific tests, such as McMurray, Apley or Thessaly tests. Examining a child's knee could be more challenging due to less cooperation and the patient's pain and anxiety.

The clinical presentation of discoid menisci varies, depending on the age, stability and presence or absence of meniscal tears. Discoid menisci can be asymptomatic if stable (type 1, complete, and type 2, incomplete) and become symptomatic if a tear occurs. Symptoms of a torn or unstable discoid meniscus (type 3) include pain, instability (type 3), popping and snapping ('snapping knee syndrome'—heard and felt), lack of terminal extension (inability to achieve full knee extension) and positive McMurray test, frequently with a loud click or snap that is heard and felt.<sup>16 42</sup> These symptoms and signs are generally intermittent and frequently occur spontaneously. A lateral joint line bulge with full flexion may be present in an unstable subluxated lateral discoid meniscus (type 3).

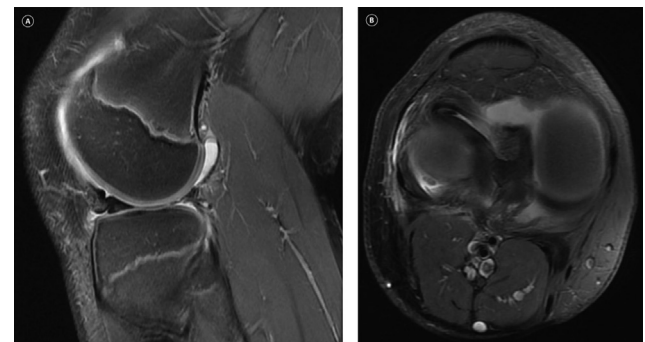
It is important to perform a detailed physical exam of the affected and unaffected knee and to obtain appropriate imaging studies. Alternative conditions should be considered as part of the differential diagnosis, such as ACL tear, osteochondritis dissecans, patellar dislocation or subluxation, pathological plica, loose bodies, and osteochondral or physeal fractures.

*Imaging studies*

Initial radiographic evaluation is indicated in skeletally immature patients with suspected meniscus injuries to rule out the aforementioned



**Fig. 4.** DLM in the right knee of an adolescent. (A) Radiographic, anteroposterior view: widening of the lateral femoral–tibial space—an indirect sign of a DLM. (B) MRI, coronal view: tear on a DLM. DLM, discoid lateral meniscus.



**Fig. 5.** Bucket-handle tear of the lateral meniscus with a large fragment in the intercondylar notch seen in the MRI of an adolescent with a locked knee. (A) Sagittal view with discoid meniscal instability signs: meniscal megahorn, 'too much meniscus' sign and 'crimped meniscus' sign on the anterior horn. (B) Axial view: anterior displacement of the posterior horn.

conditions. Radiographs are often normal in patients with a discoid meniscus; however, they may reveal indirect radiological signs, such as widening of the joint space up to 11 mm (figure 4A), flattening of the femoral condyle and presence of other related conditions as described in box 1.

MRI is useful in detecting the presence of a meniscal tear (figure 5) or is performed as part of preoperative evaluation. MRI has a lower sensitivity and specificity for detecting of meniscal injuries in the young population. A child's meniscus has high meniscal vascularity, causing signs of intrameniscal enhancement on MRI, and can consequently present as a meniscal tear leading to false positives.<sup>43</sup> Furthermore, according to Bouju *et al*, MRI overestimates medial and underestimates lateral meniscal lesions when compared with diagnostic arthroscopy (figure 6).<sup>44</sup> Discoid meniscus can be diagnosed by MRI when three or more consecutive sagittal sections (5 mm-thick slices) demonstrate a continuity of the meniscus between the anterior and posterior horns (bow-tie sign) (figure 4B).<sup>18</sup> MRI can also be used to evaluate meniscal integrity, stability, residual healing and anatomy after discoid meniscal surgery.<sup>45 46</sup> Furthermore, discoid meniscal instability signs include meniscal shift, meniscal megahorn, 'pseudo-bucket-handle tear', 'too much meniscus' sign, 'crimped meniscus' sign (thickened, displaced, unstable lateral discoid meniscus on the sagittal view) (figure 5A) and parameniscal oedema.<sup>47</sup> (box 2)

**Box 2**

Essential typical features of diagnostic evaluation and surgical procedures

- Radiological indirect signs of discoid meniscus are widening of the joint space and flattening of the femoral condyle.
- MRI discoid meniscus signs diagnostic signs are: continuity of the meniscus between the anterior and posterior horns (bow-tie sign); meniscal shift; meniscal megahorn; 'pseudo-bucket-handle tear'; 'too much meniscus' sign; 'crimped meniscus' sign;(figure 5A) and parameniscal oedema.<sup>47</sup>
- Saucerization can be challenging due to a limited visualization from a small knee and thickened discoid meniscus. Surgical tips can include a low-profile straight basket to start a path through the central portion of the discoid meniscus. For the midbody, a side-basket can be helpful for trimming. For the anterior horn, a back basket or meniscal knife can be useful. The oscillating shaver should be then applied to gently smooth the remaining shape of the inner meniscus rim.
- After saucerization, a probe should be used and meniscal instability should be treated with meniscal repair to the capsule.

**General treatment concepts**

The treatment of meniscal tear injuries in children and adolescents usually follows the same principles as the one in the adult population, with a specific focus on meniscal repair. There are four different treatment options according to the '4 Rs' proposal: "retain" (conservative), "resect" (meniscectomy), "repair" or "replace" (meniscal scaffold or MAT). These four treatment indications are explained in table 1.

In paediatric patients, the majority of meniscal tears are large and symptomatic, usually requiring surgical treatment.<sup>29 30 48</sup> In case of conservative treatment, pivoting sports activities should be avoided for 12 weeks.<sup>49 50</sup>

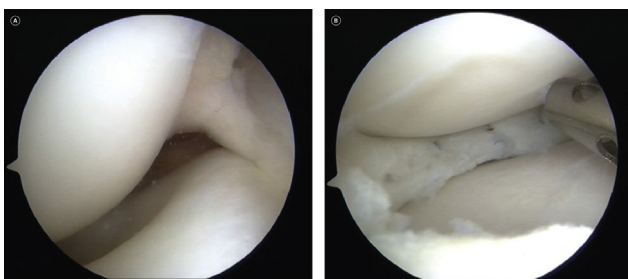
We do not recommend treatment of asymptomatic incidental meniscus tears/discoid meniscus or to do 'prophylactic' saucerisation before the onset of symptoms. However, observation of those findings is highly recommended, especially in this type of population.

**Types of tears, treatment and outcomes**

The pattern of meniscal tears in children tends to present as a longitudinal peripheral or bucket handle in the R-R meniscal zone.<sup>51</sup>

The reported outcome of total or subtotal meniscectomy in the paediatric population is poor and leads to early arthrosis at a faster pace compared with adults.<sup>7 38</sup>

Manzione *et al*<sup>38</sup> analysed the long-term results of 20 children and adolescents treated with partial or total meniscectomy, with an average 5.5-year follow-up. They found that 75% of patients were still symptomatic; 80% had radiographic changes consistent with early OA; and 60% were dissatisfied with the postsurgical outcome.



**Fig. 6.** Lateral discoid meniscus in the right knee. (A) Arthroscopic intercondylar view. (B) After saucerisation and repair.

**Table 1**

Treatment options and indications for meniscal injuries.

Surgical procedure	Indications
Meniscus retention (conservative treatment)	<ul style="list-style-type: none"> <li>• Asymptomatic meniscal tears and asymptomatic discoid meniscus.</li> <li>• Non-displaced stable peripheral tears measuring 10 mm or less in length that involve the outer 10%–30% of the meniscus (vascular region) and are manually displaceable by less than 3 mm.</li> <li>• Small radial tears measuring 3 mm or less.</li> </ul>
Meniscus resection (meniscectomy)	<ul style="list-style-type: none"> <li>• Chronic tears.</li> <li>• Avascular zone involvement (inner third of the meniscus, W-W zone).</li> <li>• Complex tears.</li> <li>• Symptomatic discoid meniscus tears: saucerisation±meniscus repair.</li> <li>• Symptomatic unstable discoid meniscus: saucerisation and meniscus repair.</li> </ul>
Meniscus repair	<ul style="list-style-type: none"> <li>• Acute tears (better before 8 weeks).</li> <li>• Peripheral vascularised zone (middle and outer third of the meniscus, R-R and R-W zones).</li> <li>• Non-damaged bucket-handle tears.</li> <li>• Stable knee.</li> <li>• Better outcomes: acute, young age; peripheral tear; longitudinal vertical tear; lateral meniscus; associated with ACL reconstruction.</li> <li>• Inside-out: posterior horn and meniscal body (mid-horn); bucket-handle tears</li> <li>• Outside-in: anterior horn and meniscal body (mid-horn).</li> <li>• All-inside: posterior horn of lateral meniscus and meniscal body (mid-horn).</li> </ul>
Meniscus replacement (meniscal scaffold and meniscal allograft transplantation)	<ul style="list-style-type: none"> <li>• Symptomatic meniscal-deficiency knee.</li> <li>• Postmeniscectomy syndrome.</li> <li>• Neutral alignment.</li> <li>• Stable knee.</li> </ul>

ACL, anterior cruciate ligament; R-R, Red-Red; R-W, Red-White; W-W, White-White.

There is a consensus among published studies that meniscal tears have greater healing potential in children and adolescents. Attempts at studying long-term outcomes of meniscal repair should be strongly considered in this age group to help us define the importance of healing potential.<sup>52</sup> Meniscus repair is strongly indicated in cases of middle one-third and outer one-third tears (vascular zone), longitudinal vertical tears and concomitant meniscus repair with ACL reconstruction.

Mintzer *et al* reported a 100% clinical healing rate of 29 meniscal repairs in 26 patients younger than 17 years of age seen for follow-up at an average of 5 years.<sup>53</sup> Noyes and Barber-Westin reported a meniscal repair healing success rate of 75% in patients under the age of 20 years, with a higher rate of meniscal healing in the ACL reconstruction group.<sup>54</sup> Krych *et al*<sup>55</sup> reported an overall clinical healing rate in patients 18 years and younger of 84% for simple tears, 59% for displaced bucket-handle tears and 57% for complex tears (74% overall). They found that complex tears (tear in more than one plane) have a higher healing rate if repaired at the same time with ACL reconstruction (57%) versus if repaired in isolation (13%). Eggli *et al* found an overall healing rate of 88% for the repair of isolated meniscal tears in patients under the age of 30 years and 67% in patients over the age of 30 years.<sup>56</sup> A more recent study conducted by Yang *et al* details a meniscus repair healing rate ranging from 33% to 100% with less than 40% reoperation rate.<sup>57</sup>

All types of tears can be seen in a discoid meniscus. Although symptomatic discoid menisci are usually related to a tear (types 1 and 2) or unstable discoid menisci (type 3), the presence of a horizontal cleavage tear, especially in a child younger than 10 years old, should raise suspicion of a discoid meniscus.<sup>47</sup> Symptomatic discoid menisci tears can be

debrided with adequate saucerisation, but if the tear extends into the peripheral vascular zone, a repair attempt is indicated (figure 6).

### Box 3

#### Key articles

- Medlar RC, Mandiberg JJ, Lyne ED. Meniscectomies in children. *Am J Sports Med* 1980;8:87–92.
- Ng YH, Tan SHS, Lim AKS, et al. Meniscopectomy leads to good mid-term to long-term outcomes for children and adolescents with discoid lateral meniscus. *Knee Surg Sports Traumatol Arthrosc* 2020 [Epub ahead of print: 12 Mar 2020].
- Kelly BT, Green DW. Discoid lateral meniscus in children. *Curr Opin Pediatr* 2002;14:54–61.
- Yang BW, Liotta ES, Paschos N. Outcomes of meniscus repair in children and adolescents. *Curr Rev Musculoskelet Med* 2019;12:233–8.
- Bellisari G, Samora W, Klingele K. Meniscus tears in children. *Sports Med Arthrosc Rev* 2011;19:50–5.
- Kocher MS, Logan CA, Kramer DE. Discoid lateral meniscus in children: diagnosis, management, and outcomes. *J Am Acad Orthop Surg* 2017;25:736–43.
- Andrich JT. Meniscal injuries in children and adolescents. *J Am Acad Orthop Surg* 1996;4:231–7.

In general, although the optimal surgical intervention for symptomatic discoid meniscus tears is not fully known, most surgeons prefer arthroscopic ‘normalisation’ of the discoid meniscus (meniscopectomy/saucerisation) with partial meniscectomy and/or repair rather than total meniscectomy due to poor reported long-term results.<sup>58</sup>

The goal of arthroscopic treatment for symptomatic discoid meniscus is to relieve symptoms and to prevent further meniscal degeneration through rim preservation and stabilisation after saucerisation. Peripheral stabilisation of the meniscal rim should be added in case of an unstable discoid meniscus (type 3).<sup>59</sup>

The long-term results of postsurgical treatment for discoid meniscus lesions are unknown and necessary to further refine the optimal treatment algorithm, but mid-term overall outcomes are satisfactory 15.<sup>60</sup> According to Ahn *et al*'s<sup>61</sup> study, 23 patients (28 knees) with a mean age at operation of 9 years underwent saucerisation and peripheral rim repair with a minimum follow-up of 2 years. They were able to return to their previous life activities with little or no limitation, and no reoperation was required after an average of 51 months.

### Box 4

#### Validated outcome measures and classifications

- Outerbridge classification.
- International Cartilage Repair Regeneration & Joint Preservation Society classification.
- Surgical failure/revision rate.
- Second-look arthroscopy.
- Visual Analogue Score.
- Tegner Activity-Level Scale.
- Lysholm Knee Scoring Scale.
- International Society of Arthroscopy, Knee Surgery and Orthopaedic Sports Medicine classification of meniscus tears.
- Ahlbäck classification.
- International Knee Documentation Committee.
- Knee Injury and Osteoarthritis Outcome Score.
- Short Form 12 or Short Form 36.

### Box 5

#### Key issues of patient selection

- Isolated meniscal injuries are uncommon in children under the age of 10–14 years unless associated with a discoid meniscus, but the frequency increases thereafter due to increased sports participation at this age group.
- Meniscus injuries without an anterior cruciate ligament (ACL) tear and in a non-discoid meniscus in children and adolescents are more common on the medial meniscus and are usually related to trauma.
- Discoid meniscus, acute meniscal tears associated with an ACL tear and bucket-handle meniscal tears are much more common over the lateral meniscus. The prevalence of a knee discoid meniscus is unknown due to its asymptomatic nature.
- Discoid menisci are prone to tearing and cause mechanical symptoms because of its abnormal morphology and vascularity.
- Most discoid lateral meniscus (DLM) remain asymptomatic until adulthood. If DLM is symptomatic in childhood, it is usually because of a meniscal tear (type 1 or 2) or an unstable discoid meniscus (type 3). The contralateral knee should be examined as it can be bilateral.
- All tear types can be seen with discoid meniscus. The presence of a horizontal cleavage tear, especially in a child younger than 10 years old, should raise suspicion of the presence of a discoid meniscus.
- Total or subtotal meniscectomy could lead to greater osteoarthritis (OA) in the paediatric population than in adults.
- Meniscus repair should be considered, whenever possible, for treatment of symptomatic meniscus tears in children and adolescents due to the theoretical greater healing potential at this age. Special attention should be given for middle and outer third tears (vascular zone), longitudinal vertical tears and if the meniscus repair is associated with ACL reconstruction.
- It seems that the overall healing rate for meniscus repair is higher for paediatric population when compared with adults; however, it is unclear if meniscal repair will reduce the long-term development of OA.
- Horizontal tears are very frequent in discoid meniscus and could be treated with saucerisation, but if the tear extends into the peripheral vascular zone, a repair should be attempted.
- Return-to-sports (RTS) rates after meniscus surgery are very high, with faster RTS in the following descending order: meniscectomy, meniscus repair, meniscus repair with ACL reconstruction and meniscal allograft transplantation.

Root avulsions of the medial meniscus in skeletally immature patients are rare and should be recognised and surgically repaired to avoid evolution towards early joint degeneration.<sup>62</sup> In this population, the presence of an open physis must be taken into consideration for the choice of the surgical technique to avoid potential iatrogenic growth disturbances.

The need for MAT in children is rare. Middleton *et al*'s<sup>63</sup> studied prospectively 23 patients aged 18 years or younger that had undergone MAT. They found an improvement of function and a decrease in post-operative pain. Therefore, MAT is a viable option in the paediatric population with symptomatic meniscal knee injuries and postmeniscectomy syndrome and can offer beneficial outcomes.<sup>64</sup>

**Box 6**

## Tips and tricks

- The all-inside meniscal repair can be very difficult to perform in children and adolescents because of their smaller knee size and may be necessary to modify it to an inside-out technique using a posterolateral incision and a cannula system to protect the peroneal nerve, popliteal vessels and the tibial nerve (preventing deep posterior perforation).
- For meniscal root tear fixation in the paediatric population with open physis, it can be useful to use retrodrilling or anchor devices to avoid further damage of the physis.
- To perform saucerisation and/or meniscectomy of the discoid meniscus, an additional contralateral portal (to the side of the meniscus) could be added in order to visualise the entire meniscus (anterior horn, mid-horn and posterior horn), as well as to work with a basket or a shaver (two portals contralateral to the injured meniscus—one for visualisation and the other for instruments).
- Saucerisation of the discoid meniscus can be challenging due to limited visualisation from small knee size and thickened discoid meniscus. It can be easier to perform it with the knee flexed to 90° with a varus stress applied, and starting with a low-profile straight basket punch through the central portion of the discoid meniscus.
- Saucerisation technique should be performed cautiously to a normal rim (6–8 mm) and to avoid removing too much meniscal tissue. The stability of the peripheral rim of the meniscus should be probed and, if unstable, should be treated with meniscal repair to the capsule.

**Prognostic factors**

Factors shown to correlate with increased healing rate after meniscal repair include acute injuries (less than 8 weeks), young age (skeletal immature patients), lateral meniscus tears associated with ACL reconstruction (serum factors and fibrin clots), small tears (less than 2.5 cm), vertical tears and tears in the peripheral vascularised zone (Red–White or Red–Red).<sup>29 30 56 65–71</sup> Complex and bucket-handle tears have demonstrated a higher risk of failure.<sup>57</sup>

**Box 7**

## Major pitfalls in the treatment of meniscus injuries in children and adolescents

- The evidence on meniscal injuries in a paediatric population is poor, with small size numbers and follow-up.
- The specific features of increased thickness of the discoid meniscus and smaller size/joint volume of the child/adolescent can make the surgical procedure more challenging.
- Failure to examine both knees for comparison and search for bilateral discoid meniscus could lead to misdiagnosis bilateral discoid meniscus condition.
- MRI has lower sensitivity and specificity in the detection of meniscus injuries in children and adolescents because the high vascularity of a child's meniscus can mimic meniscal tears. MRI should not be routinely performed, and images should be correlated with clinical findings to avoid overdiagnosis and unnecessary surgical procedures.
- Failure to recognise repairable meniscus tears and concomitant injuries in this young aged population could lead to avoidable complications.

**Box 8**

## Future perspectives

- Future clinical studies may help determine the best approach for each type of meniscus tear, according to the time of injury, type of tear, age of the patient and associated injuries.
- Further developments in imagiology hardware and software and interpretation of the three-dimensional configuration anatomy and vascularisation.
- Additional research is required to evaluate the protective role of techniques, such as meniscal saucerisation, meniscus repair or MAT to avoid the risk of osteoarthritis development.
- A better understanding of the anatomy, biology and evolution of discoid menisci and the role of prophylactic saucerisation to prevent or minimise further tears.
- Need for clinical trials to evaluate if biological augmentation treatments such as hyaluronic acid, platelet-rich plasma, bone marrow aspirate concentrate, fibrin clots, scaffolds, mesenchymal stem cells can substantially improve meniscal healing.
- Improvements and release of new replacement devices (scaffolds and meniscus artificial implants) and development on the surgical replacement techniques.

**Return-to-sports (RTS)**

According to available published literature, the paediatric population makes RTS full activities with little or no residual limitations after 6–12 months postoperatively. A longer RTS period is seen in the meniscus repair group (3–4 months postoperatively) when compared with the meniscectomy group (6 weeks postoperatively).<sup>27 45</sup> After meniscus repair, some sport activities can be authorised at 3 months postoperatively, such as running, swimming and cycling.<sup>45</sup> If meniscus repair is associated with ACL reconstruction, usually RTS takes longer (8 months) versus isolated meniscal repair (6 months).<sup>72</sup> Most patients treated with MAT return to high-level athletic sports, but participation in high-impact activities should be avoided.<sup>73</sup>

**Geographical differences**

Data from different studies could vary from different geographical regions and may not be generalisable due to ethnic anatomical diversity.

For instance, there is a higher incidence of discoid meniscus in Asian countries than in Western countries.<sup>74–78</sup> In a study done in South Korea, Bae *et al*<sup>74</sup> reported a high prevalence of bilateral DLM (79%), while the incidence of discoid menisci in the Greek population is quoted to be as low as 1.8%.<sup>75</sup> However, other studies from Japan<sup>76</sup> reported an incidence of 13%; in Korea, Kim *et al*<sup>77</sup> observed an incidence of 10.6%; in India, Rao *et al*<sup>78</sup> noted an incidence of 5.8%; and in the USA, Jordan<sup>79</sup> described an incidence of 3%–5%.

These data support the fact that discoid menisci can be a congenital anomaly and with a genetic or familial predisposition for its development.

**Future perspectives**

Menisci is a complex structure that plays a critical role in knee biomechanics, and proper treatments of meniscus injuries could improve clinical outcomes and avoid progression to early OA.

According to the current literature, it is crucial to early understand the clinical history and associated factors and to appropriately manage the most updated treatments for each specific meniscal injury. However, further understanding of the pathogenesis and biology of meniscal injuries in children and adolescents is needed to allow for an evidence-based patient selection of treatment options.

Future large-scale epidemiological studies are required to determine the real prevalence of meniscal tears and discoid meniscus, as well as its geographical differences between different regions around the world.

We believe that future improvements in meniscal devices will allow for more stable and complex meniscal repair configurations. In parallel, imaging advances in hardware and software will allow a more precise diagnosis and understanding of the 3D meniscus anatomy and vascularisation.

Biological augmentation (hyaluronic acid, platelet-rich plasma, bone marrow aspirate concentrate, fibrin clots, stem cells and biological augmentation membranes) will potentially enhance meniscal healing potential and promote tissue regrowth, especially in avascular zone. These treatments can also play a role in conservative approaches. Furthermore, future replacement devices (scaffolds and meniscus artificial implants) and better surgical techniques will be also a reality.

Prospective randomised control trials are needed to determine the safety and clinical efficacy of these treatments in a clinical setting, in order to provide the best care for our young patients.

## Contributors

All the authors (GV, FC, KA and PDH) have made the following contributions: substantial contributions to the conception or design of the work; or the acquisition, analysis, or interpretation of data for the work; drafting the work or revising it critically for important intellectual content; final approval of the version to be published; and agreement to be accountable for all aspects of the work in ensuring that questions related to the accuracy or integrity of any part of the work are appropriately investigated and resolved.

## Funding

The authors have not declared a specific grant for this research from any funding agency in the public, commercial or not-for-profit sectors.

## Patient consent for publication

Not required.

## Open access

This is an open access article distributed in accordance with the Creative Commons Attribution Non Commercial (CC BY-NC 4.0) license, which permits others to distribute, remix, adapt, build upon this work non-commercially, and license their derivative works on different terms, provided the original work is properly cited, an indication of whether changes were made, and the use is non-commercial. See: <http://creativecommons.org/licenses/by-nc/4.0/>.

## Competing interests

None declared.

## References

- Allen PR, Denham RA, Swan AV. Late degenerative changes after meniscectomy. factors affecting the knee after operation. *J Bone Joint Surg Br* 1984;66:666–71. <https://doi.org/10.1302/0301-620X.66B5.6548755>. <http://www.ncbi.nlm.nih.gov/pubmed/6548755>.
- Fairbank TJ. Knee joint changes after meniscectomy. *J Bone Joint Surg Br* 1948;30-B:664–70. <https://doi.org/10.1302/0301-620X.30B4.664>. <http://www.ncbi.nlm.nih.gov/pubmed/18894618>.
- Medlar RC, Mandiberg JJ, Lyne ED. Meniscectomies in children. *Am J Sports Med* 1980;8:87–92. <https://doi.org/10.1177/036354658000800205>.
- Bonneux I, Vandekerckhove B. Arthroscopic partial lateral meniscectomy long-term results in athletes. *Acta Orthop Belg* 2002;68:356–61. <http://www.ncbi.nlm.nih.gov/pubmed/12415937>.
- McDermott ID, Amis AA. The consequences of meniscectomy. *J Bone Joint Surg Br* 2006;88-B:1549–56. <https://doi.org/10.1302/0301-620X.88B12.18140>. <http://www.ncbi.nlm.nih.gov/pubmed/17159163>.
- Kopf S, Beaufils P, Hirschmann MT, et al. Management of traumatic meniscus tears: the 2019 ESSKA meniscus consensus. *Knee Surg Sports Traumatol Arthrosc* 2020;28:1177–94. <https://doi.org/10.1007/s00167-020-05847-3>. <http://www.ncbi.nlm.nih.gov/pubmed/32052121>.
- Baratz ME, Fu FH, Mengato R. Meniscal tears: the effect of meniscectomy and of repair on intraarticular contact areas and stress in the human knee. A preliminary report. *Am J Sports Med* 1986;14:270–5. <https://doi.org/10.1177/036354658601400405>. <http://www.ncbi.nlm.nih.gov/pubmed/3755296>.
- Beaufils P, Becker R, Kopf S, et al. Surgical management of degenerative meniscus lesions: the 2016 ESSKA meniscus consensus. *Knee Surg Sports Traumatol Arthrosc* 2017;25:335–46. <https://doi.org/10.1007/s00167-016-4407-4>. <http://www.ncbi.nlm.nih.gov/pubmed/28210788>.
- Kushare I, Klingele K, Samora W. Discoid meniscus: diagnosis and management. *Orthop Clin North Am* 2015;46:533–40. <https://doi.org/10.1016/j.oct.2015.06.007>. <http://www.ncbi.nlm.nih.gov/pubmed/26410641>.
- Ahn JH, Shim JS, Hwang CH, et al. Discoid lateral meniscus in children: clinical manifestations and morphology. *J Pediatr Orthop* 2001;21:812–6. <https://doi.org/10.1097/01241398-200111000-00022>. <http://www.ncbi.nlm.nih.gov/pubmed/11675561>.
- Dickhaut SC, DeLee JC. The discoid lateral-meniscus syndrome. *J Bone Joint Surg Am* 1982;64:1068–73. <https://doi.org/10.2106/00004623-198264070-00018>. <http://www.ncbi.nlm.nih.gov/pubmed/7118974>.
- Fleissner PR, Eilert RE. Discoid lateral meniscus. *Am J Knee Surg* 1999;12:125–31. <http://www.ncbi.nlm.nih.gov/pubmed/10323506>.
- Ikeuchi H. Arthroscopic treatment of the discoid lateral meniscus. technique and long-term results. *Clin Orthop Relat Res* 1982;167:19–28. <https://doi.org/10.1097/00003086-198207000-00005>. <http://www.ncbi.nlm.nih.gov/pubmed/6896480>.
- Smillie IS. The congenital discoid meniscus. *J Bone Joint Surg Br* 1948;30B:671–82. <https://doi.org/10.1302/0301-620X.30B4.671>. <http://www.ncbi.nlm.nih.gov/pubmed/18894619>.
- Ng YH, Tan SHS, Lim AKS, et al. Meniscopectomy leads to good mid-term to long-term outcomes for children and adolescents with discoid lateral meniscus. *Knee Surg Sports Traumatol Arthrosc* 2020. <https://doi.org/10.1007/s00167-020-05929-2> [Epub ahead of print: 12 Mar 2020]. <http://www.ncbi.nlm.nih.gov/pubmed/32166389>.
- Andrish JT. Meniscal injuries in children and adolescents: diagnosis and management. *J Am Acad Orthop Surg* 1996;4:231–7. <https://doi.org/10.5435/00124635-199609000-00001>. <http://www.ncbi.nlm.nih.gov/pubmed/10795058>.
- Mitchell J, Graham W, Best TM, et al. Epidemiology of meniscal injuries in US high school athletes between 2007 and 2013. *Knee Surg Sports Traumatol Arthrosc* 2016;24:715–22. <https://doi.org/10.1007/s00167-015-3814-2>. <http://www.ncbi.nlm.nih.gov/pubmed/26506845>.
- Stanitski CL, Harvell JC, Fu F. Observations on acute knee hemarthrosis in children and adolescents. *J Pediatr Orthop* 1993;13:506–10. <https://doi.org/10.1097/01241398-199307000-00016>. <http://www.ncbi.nlm.nih.gov/pubmed/8370785>.
- Samora WP, Palmer R, Klingele KE. Meniscal pathology associated with acute anterior cruciate ligament tears in patients with open physes. *J Pediatr Orthop* 2011;31:272–6. <https://doi.org/10.1097/BPO.0b013e31820f6b8>. <http://www.ncbi.nlm.nih.gov/pubmed/21415686>.
- Malatray M, Raux S, Peltier A, et al. Ramp lesions in ACL deficient knees in children and adolescent population: a high prevalence confirmed in intercondylar and posteromedial exploration. *Knee Surg Sports Traumatol Arthrosc* 2018;26:1074–9. <https://doi.org/10.1007/s00167-017-4471-4>. <http://www.ncbi.nlm.nih.gov/pubmed/28332046>.
- Bellisari G, Samora W, Klingele K. Meniscus tears in children. *Sports Med Arthrosc Rev* 2011;19:50–5. <https://doi.org/10.1097/JSA.0b013e318204d01a>. <http://www.ncbi.nlm.nih.gov/pubmed/21293238>.
- Carter CW, Kocher MS. Meniscus repair in children. *Clin Sports Med* 2012;31:135–54. <https://doi.org/10.1016/j.csm.2011.09.002>. <http://www.ncbi.nlm.nih.gov/pubmed/22108664>.
- Jeannopoulos CL. Observations on discoid menisci. *J Bone Joint Surg Am* 1950;32-A:649–52. <https://doi.org/10.2106/00004623-195032030-00019>. <http://www.ncbi.nlm.nih.gov/pubmed/15428488>.
- Ahn JH, Lee SH, Yoo JC, et al. Bilateral discoid lateral meniscus in knees: evaluation of the contralateral knee in patients with symptomatic discoid lateral meniscus. *Arthroscopy* 2010;26:1348–56. <https://doi.org/10.1016/j.arthro.2010.02.008>. <http://www.ncbi.nlm.nih.gov/pubmed/20729026>.
- Fu FH, Baratz M. Meniscal injuries. In: DeLee JC, Drez D, eds. *Orthopaedic sports medicine: principles and practice*, 2. Philadelphia: WB Saunders; 1994. p. 1146–62.
- Shieh A, Bastrom T, Roocroft J, et al. Meniscus tear patterns in relation to skeletal immaturity: children versus adolescents. *Am J Sports Med* 2013;41:2779–83. <https://doi.org/10.1177/0363546513504286>. <http://www.ncbi.nlm.nih.gov/pubmed/24071370>.
- Kramer H, Kalish LA, Martin DJ, et al. Outcomes after the operative treatment of Bucket-Handle meniscal tears in children and adolescents. *Orthop J Sports Med* 2019;7. <https://doi.org/10.1177/2325967118820305>. <http://www.ncbi.nlm.nih.gov/pubmed/30729144>.
- Kaplan EB. Discoid lateral meniscus of the knee joint. *Bull Hosp Joint Dis* 1955;16:111–24.
- Greis PE, Bardana DD, Holmstrom MC, et al. Meniscal injury: I. basic science and evaluation. *J Am Acad Orthop Surg* 2002;10:168–76. <https://doi.org/10.5435/00124635-200205000-00003>. <http://www.ncbi.nlm.nih.gov/pubmed/12041938>.
- Greis PE, Holmstrom MC, Bardana DD, et al. Meniscal injury: II. management. *J Am Acad Orthop Surg* 2002;10:177–87. <https://doi.org/10.5435/00124635-200205000-00004>. <http://www.ncbi.nlm.nih.gov/pubmed/12041939>.

- 31 Francavilla ML, Restrepo R, Zamora KW, et al. Meniscal pathology in children: differences and similarities with the adult meniscus. *Pediatr Radiol* 2014;44:910–25. <https://doi.org/10.1007/s00247-014-3022-0>. <http://www.ncbi.nlm.nih.gov/pubmed/25060615>.
- 32 Bisicchia S, Botti F, Tudisco C. Discoid lateral meniscus in children and adolescents: a histological study. *J Exp Orthop* 2018;5:39. <https://doi.org/10.1186/s40634-018-0153-5>. <http://www.ncbi.nlm.nih.gov/pubmed/30251229>.
- 33 Hart ES, Kalra KP, Grottkau BE, et al. Discoid lateral meniscus in children. *Orthop Nurs* 2008;27:174–9. <https://doi.org/10.1097/01.NOR.0000320545.35858.04>. <http://www.ncbi.nlm.nih.gov/pubmed/18521032>.
- 34 Yaniv M, Blumberg N. The discoid meniscus. *J Child Orthop* 2007;1:89–96. <https://doi.org/10.1007/s11832-007-0029-1>. <http://www.ncbi.nlm.nih.gov/pubmed/19308479>.
- 35 Aydın Kabakçı AD, Büyükmumcu M, Akin D, et al. Morphological structure and variations of fetal lateral meniscus: the significance in convenient diagnosis and treatment. *Knee Surg Sports Traumatol Arthrosc* 2019;27:3364–73. <https://doi.org/10.1007/s00167-019-05352-2>. <http://www.ncbi.nlm.nih.gov/pubmed/30656371>.
- 36 Watanabe M. *Arthroscopy of the knee joint. In: disorders of the knee. Philadelphia: Lippincott; 1974. p. 145–59.*
- 37 Kelly BT, Green DW. Discoid lateral meniscus in children. *Curr Opin Pediatr* 2002;14:54–61. <https://doi.org/10.1097/00008480-200202000-00010>. <http://www.ncbi.nlm.nih.gov/pubmed/11880735>.
- 38 Manziane M, Pizzutillo PD, Peoples AB, et al. Meniscectomy in children: a long-term follow-up study. *Am J Sports Med* 1983;11:111–5. <https://doi.org/10.1177/036354658301100301>. <http://www.ncbi.nlm.nih.gov/pubmed/6688155>.
- 39 Busch MT. Meniscal injuries in children and adolescents. *Clin Sports Med* 1990;9:661–80. [https://doi.org/10.1016/S0278-5919\(20\)30715-8](https://doi.org/10.1016/S0278-5919(20)30715-8). <http://www.ncbi.nlm.nih.gov/pubmed/2199076>.
- 40 Terzidis IP, Christodoulou A, Ploumis A, et al. Meniscal tear characteristics in young athletes with a stable knee: arthroscopic evaluation. *Am J Sports Med* 2006;34:1170–5. <https://doi.org/10.1177/0363546506287939>. <http://www.ncbi.nlm.nih.gov/pubmed/16685089>.
- 41 Chambers HG, Chambers RC. The natural history of meniscus tears. *J Pediatr Orthop* 2019;39:S53–5. <https://doi.org/10.1097/BPO.0000000000001386>. <http://www.ncbi.nlm.nih.gov/pubmed/31169650>.
- 42 Washington ER, Root L, Liener UC. Discoid lateral meniscus in children. long-term follow-up after excision. *J Bone Joint Surg Am* 1995;77:1357–61. <https://doi.org/10.2106/00004623-199509000-00011>. <http://www.ncbi.nlm.nih.gov/pubmed/7673286>.
- 43 Stanitski CL. Correlation of arthroscopic and clinical examinations with magnetic resonance imaging findings of injured knees in children and adolescents. *Am J Sports Med* 1998;26:2–6. <https://doi.org/10.1177/03635465980260012001>. <http://www.ncbi.nlm.nih.gov/pubmed/9474394>.
- 44 Bouju Y, Carpentier E, Bergerault F, et al. The concordance of MRI and arthroscopy in traumatic meniscal lesions in children. *Orthop Traumatol Surg Res* 2011;97:712–8. <https://doi.org/10.1016/j.otsr.2011.07.010>. <http://www.ncbi.nlm.nih.gov/pubmed/22000285>.
- 45 Wasser L, Knörr J, Accaddled F, et al. Arthroscopic treatment of discoid meniscus in children: clinical and MRI results. *Orthop Traumatol Surg Res* 2011;97:297–303. <https://doi.org/10.1016/j.otsr.2010.11.009>. <http://www.ncbi.nlm.nih.gov/pubmed/21435965>.
- 46 Mayer-Wagner S, von Liebe A, Horng A, et al. Discoid lateral meniscus in children: magnetic resonance imaging after arthroscopic resection. *Knee Surg Sports Traumatol Arthrosc* 2011;19:1920–4. <https://doi.org/10.1007/s00167-011-1523-z>. <http://www.ncbi.nlm.nih.gov/pubmed/21541709>.
- 47 Restrepo R, Weisberg MD, Pevsner R, et al. Discoid meniscus in the pediatric population: emphasis on MR imaging signs of instability. *Magn Reson Imaging Clin N Am* 2019;27:323–39. <https://doi.org/10.1016/j.mric.2019.01.009>. <http://www.ncbi.nlm.nih.gov/pubmed/30910101>.
- 48 Kocher MS, Micheli LJ. *The pediatric knee: evaluation and treatment. In: Insall JN, Scott WN, eds. Surgery of the knee. 3rd edition. New York: Churchill-Livingstone; 2001. p. 1356–97.*
- 49 Weiss CB, Lundberg M, Hamberg P, et al. Non-Operative treatment of meniscal tears. *J Bone Joint Surg Am* 1989;71:811–22. <https://doi.org/10.2106/00004623-198971060-00003>. <http://www.ncbi.nlm.nih.gov/pubmed/2745476>.
- 50 Kocher MS, Klingele K, Rassman SO. Meniscal disorders: normal, discoid, and cysts. *Orthop Clin North Am* 2003;34:329–40. [https://doi.org/10.1016/s0030-5898\(03\)00008-7](https://doi.org/10.1016/s0030-5898(03)00008-7). <http://www.ncbi.nlm.nih.gov/pubmed/12974483>.
- 51 Kraus T, Heidari N, Švehlík M, et al. Outcome of repaired unstable meniscal tears in children and adolescents. *Acta Orthop* 2012;83:261–6. <https://doi.org/10.3109/17453674.2012.693017>. <http://www.ncbi.nlm.nih.gov/pubmed/22616744>.
- 52 Haskel JD, Uppstrom TJ, Dare DM, et al. Decline in clinical scores at long-term follow-up of arthroscopically treated discoid lateral meniscus in children. *Knee Surg Sports Traumatol Arthrosc* 2018;26:2906–11. <https://doi.org/10.1007/s00167-017-4825-y>. <http://www.ncbi.nlm.nih.gov/pubmed/29305617>.
- 53 Mintzer CM, Richmond JC, Taylor J. Meniscal repair in the young athlete. *Am J Sports Med* 1998;26:630–3. <https://doi.org/10.1177/03635465980260050601>. <http://www.ncbi.nlm.nih.gov/pubmed/9784808>.
- 54 Noyes FR, Barber-Westin SD. Arthroscopic repair of meniscal tears extending into the avascular zone in patients younger than twenty years of age. *Am J Sports Med* 2002;30:589–600. <https://doi.org/10.1177/03635465020300042001>. <http://www.ncbi.nlm.nih.gov/pubmed/12130415>.
- 55 Krych AJ, Pitts RT, Dajani KA, et al. Surgical repair of meniscal tears with concomitant anterior cruciate ligament reconstruction in patients 18 years and younger. *Am J Sports Med* 2010;38:976–82. <https://doi.org/10.1177/0363546509354055>. <http://www.ncbi.nlm.nih.gov/pubmed/20299545>.
- 56 Eggli S, Wegmüller H, Kosina J, et al. Long-Term results of arthroscopic meniscal repair. An analysis of isolated tears. *Am J Sports Med* 1995;23:715–20. <https://doi.org/10.1177/036354659502300614>. <http://www.ncbi.nlm.nih.gov/pubmed/8600740>.
- 57 Yang BW, Liotta ES, Paschos N. Outcomes of meniscus repair in children and adolescents. *Curr Rev Musculoskelet Med* 2019;12:233–8. <https://doi.org/10.1007/s12178-019-09554-6>.
- 58 Mosich GM, Lieu V, Ebrahimzadeh E, et al. Operative treatment of isolated meniscus injuries in adolescent patients: a meta-analysis and review. *Sports Health* 2018;10:311–6. <https://doi.org/10.1177/1941738118768201>. <http://www.ncbi.nlm.nih.gov/pubmed/29648924>.
- 59 Carabajal M, Allende GJ, Masquijo JJ. Mid-Term results of arthroscopic remodelling combined with peripheral repair in children with unstable discoid meniscus. *Rev Esp Cir Ortop Traumatol* 2020;64:206–12. <https://doi.org/10.1016/j.recote.2020.03.004>. <http://www.ncbi.nlm.nih.gov/pubmed/31826819>.
- 60 Ahn JH, Kim K-I, Wang JH, et al. Long-Term results of arthroscopic reshaping for symptomatic discoid lateral meniscus in children. *Arthroscopy* 2015;31:867–73. <https://doi.org/10.1016/j.arthro.2014.12.012>. <http://www.ncbi.nlm.nih.gov/pubmed/25665957>.
- 61 Ahn JH, Lee SH, Yoo JC, et al. Arthroscopic partial meniscectomy with repair of the peripheral tear for symptomatic discoid lateral meniscus in children: results of minimum 2 years of follow-up. *Arthroscopy* 2008;24:888–98. <https://doi.org/10.1016/j.arthro.2008.03.002>. <http://www.ncbi.nlm.nih.gov/pubmed/18657737>.
- 62 Sonnery-Cottet B, Mortati R, Archbold P, et al. Root avulsion of the posterior horn of the medial meniscus in skeletally immature patients. *Knee* 2014;21:1291–6. <https://doi.org/10.1016/j.knee.2014.07.001>. <http://www.ncbi.nlm.nih.gov/pubmed/25115656>.
- 63 Middleton S, Asplin L, Stevenson C, et al. Meniscal allograft transplantation in the paediatric population: early referral is justified. *Knee Surg Sports Traumatol Arthrosc* 2019;27:1908–13. <https://doi.org/10.1007/s00167-019-05437-y>. <http://www.ncbi.nlm.nih.gov/pubmed/30820601>.
- 64 Riboh JC, Tilton AK, Cvetanovich GL, et al. Meniscal allograft transplantation in the adolescent population. *Arthroscopy* 2016;32:1133–40. <https://doi.org/10.1016/j.arthro.2015.11.041>. <http://www.ncbi.nlm.nih.gov/pubmed/26906460>.
- 65 Kocher MS, Logan CA, Kramer DE. Discoid lateral meniscus in children: diagnosis, management, and outcomes. *J Am Acad Orthop Surg* 2017;25:736–43. <https://doi.org/10.5435/JAAOS-D-15-00491>. <http://www.ncbi.nlm.nih.gov/pubmed/29059110>.
- 66 Cannon WD, Vittori JM. The incidence of healing in arthroscopic meniscal repairs in anterior cruciate ligament-reconstructed knees versus stable knees. *Am J Sports Med* 1992;20:176–81. <https://doi.org/10.1177/036354659202000214>. <http://www.ncbi.nlm.nih.gov/pubmed/1558246>.
- 67 Rubman MH, Noyes FR, Barber-Westin SD. Arthroscopic repair of meniscal tears that extend into the avascular zone. A review of 198 single and complex tears. *Am J Sports Med* 1998;26:87–95. <https://doi.org/10.1177/03635465980260013301>. <http://www.ncbi.nlm.nih.gov/pubmed/9474408>.
- 68 Buseck MS, Noyes FR. Arthroscopic evaluation of meniscal repairs after anterior cruciate ligament reconstruction and immediate motion. *Am J Sports Med* 1991;19:489–94. <https://doi.org/10.1177/036354659101900512>. <http://www.ncbi.nlm.nih.gov/pubmed/1962715>.
- 69 Tenuta JJ, Arciero RA. Arthroscopic evaluation of meniscal repairs. factors that effect healing. *Am J Sports Med* 1994;22:797–802. <https://doi.org/10.1177/036354659402200611>. <http://www.ncbi.nlm.nih.gov/pubmed/7856804>.
- 70 Tengrotenhuysen M, Meeremans G, Pittoors K, et al. Long-Term outcome after meniscal repair. *Knee Surg Sports Traumatol Arthrosc* 2011;19:236–41. <https://doi.org/10.1007/s00167-010-1286-y>. <http://www.ncbi.nlm.nih.gov/pubmed/20953762>.
- 71 Ferrari MB, Murphy CP, Gomes JLE. Meniscus repair in children and adolescents: a systematic review of treatment approaches, meniscal healing, and outcomes. *J Knee Surg* 2019;32:490–8. <https://doi.org/10.1055/s-0038-1653943>. <http://www.ncbi.nlm.nih.gov/pubmed/29791926>.
- 72 Nishino K, Hashimoto Y, Nishida Y, et al. Incidence and risk factors for meniscal cyst after meniscal repair. *Arthroscopy* 2019;35:1222–9. <https://doi.org/10.1016/j.arthro.2018.11.039>. <http://www.ncbi.nlm.nih.gov/pubmed/30871908>.
- 73 Tuca M, Luderowski E, Rodeo S. Meniscal transplant in children. *Curr Opin Pediatr* 2016;28:47–54. <https://doi.org/10.1097/MOP.0000000000000306>. <http://www.ncbi.nlm.nih.gov/pubmed/26709681>.
- 74 Bae J-H, Lim H-C, Hwang D-H, et al. Incidence of bilateral discoid lateral meniscus in an Asian population: an arthroscopic assessment of contralateral knees. *Arthroscopy* 2012;28:936–41. <https://doi.org/10.1016/j.arthro.2011.12.003>. <http://www.ncbi.nlm.nih.gov/pubmed/22365266>.
- 75 Papadopoulos A, Karathanasis A, Kirkos JM, et al. Epidemiologic, clinical and arthroscopic study of the discoid meniscus variant in Greek population. *Knee Surg Sports Traumatol Arthrosc* 2009;17:600–6. <https://doi.org/10.1007/s00167-008-0703-y>. <http://www.ncbi.nlm.nih.gov/pubmed/19132346>.
- 76 Fukuta S, Masaki K, Korai F. Prevalence of abnormal findings in magnetic resonance images of asymptomatic knees. *J Orthop Sci* 2002;7:287–91. <https://doi.org/10.1007/s007760200049>. <http://www.ncbi.nlm.nih.gov/pubmed/12077651>.
- 77 Kim SJ, Lee YT, Kim DW. Intraarticular anatomic variants associated with discoid meniscus in Koreans. *Clin Orthop Relat Res* 1998;356:202–7. <https://doi.org/10.1097/00003086-199811000-00027>. <http://www.ncbi.nlm.nih.gov/pubmed/9917685>.
- 78 Rao PS, Rao SK, Paul R. Clinical, radiologic, and arthroscopic assessment of discoid lateral meniscus. *Arthroscopy* 2001;17:275–7. <https://doi.org/10.1053/jars.2001.19973>. <http://www.ncbi.nlm.nih.gov/pubmed/11239348>.
- 79 Jordan MR. Lateral meniscal variants: evaluation and treatment. *J Am Acad Orthop Surg* 1996;4:191–200. <https://doi.org/10.5435/00124635-199607000-00003>. <http://www.ncbi.nlm.nih.gov/pubmed/10795054>.