

## Technical Note

# Percutaneous Lateral Collateral Ligament Release for Arthroscopic Procedures of the Knee: The “Lateral Pie-Crusting”

Gonzalo Samitier, M.D., Ph.D., Joel Gambín, M.D., Iván Saenz, M.D., and Gustavo Vinagre, M.D., Ph.D.

**Abstract:** Arthroscopy of the knee is among the most frequent procedures worldwide in orthopaedic surgery. To avoid iatrogenic cartilage injury, adequate visualization and working space are mandatory to perform complex procedures. Narrow femorotibial joint space is often encountered, and it is challenging to obtain consistent satisfactory results. Medial collateral ligament release is safe and reliable for facilitating medial joint widening. Current clinical studies support lateral collateral ligament (LCL) healing capacity in isolated injuries. This article describes a simple, safe, and reproducible technique of LCL release through a multiple-puncture method to facilitate lateral compartment visualization and instrumentation, the so-called lateral pie-crusting.

**K**nee arthroscopy is one of the most performed orthopaedic procedures.<sup>1</sup> Surgical complexity in meniscal repair, meniscal allograft transplantation, and other advanced procedures demand the need for proper identification and knowledge of anatomic structures. Femorotibial joint space is often narrow, decreasing arthroscopic visualization. This provides a limited working space that can hinder technical execution and create articular damage that might influence outcomes.<sup>2</sup> Compton et al.<sup>3</sup> have reported an evident iatrogenic cartilage injury incidence of 35.4%.

Different methods have been published to improve arthroscopic visualization and increase femorotibial space.<sup>4-6</sup> These methods have been described and are focused exclusively on the medial compartment. The medial collateral ligament (MCL) release, the so-called pie-crusting technique, is a frequent surgical procedure that seems safe without producing residual medial

knee instability.<sup>7</sup> Several cadaveric studies have shown that the bony geometry of the medial compartment makes it inherently stable and with the potential of the MCL to heal.<sup>8</sup> On the other hand, lateral knee injuries have been described as having less healing capacity, leading to varus instability.<sup>9,10</sup> However, this argument could be biased by the joint involvement of multiple damaged structures of the posterolateral corner (PLC). Recent studies have shown that isolated lateral collateral ligament (LCL) injuries have potential healing, especially grade 1 and 2 tears, that can be managed conservatively.<sup>11-13</sup> Surgical indications for LCL repair or reconstruction should include grade 3 LCL injuries and multiligament knee injuries involving the LCL.<sup>13,14</sup>

This Technical Note describes a percutaneous LCL release potentially useful for arthroscopic procedures to allow greater access and working space to the lateral compartment of the knee.

*From the Department of Orthopaedic Surgery and Traumatology, Centro Médico Quirónsalud Aribau, Barcelona, Spain (G.S.); Department of Orthopaedic Surgery and Traumatology, Instituto Musculoesquelético Europeo, IMSKE, Valencia, Spain (J.G.); Department of Orthopaedic Surgery and Traumatology, Fundació Hospital de l'Esperit Sant, Santa Coloma de Gramenet, Barcelona, Spain (I.S.); Department of Human Anatomy, Universidad de Barcelona, Barcelona, Spain (I.S.); Department of Orthopaedic Surgery and Traumatology, Complexo Hospitalar do Médio Ave, Porto, Portugal (G.V.); and Department of Orthopaedic Surgery and Traumatology, Hospital Lusíadas, Porto, Portugal (G.V.).*

*The authors report that they have no conflicts of interest in the authorship and publication of this article. Full ICMJE author disclosure forms are available for this article online, as [supplementary material](#).*

*Received June 14, 2022; accepted August 24, 2022.*

*Address correspondence to Gustavo Vinagre, M.D., Ph.D., Department of Orthopaedic Surgery and Traumatology, Complexo Hospitalar do Médio Ave, Porto, Portugal, and Department of Orthopaedic Surgery and Traumatology, Hospital Lusíadas Porto, Porto, Portugal. E-mail: [gustavovinagre@gustavovinagre.com](mailto:gustavovinagre@gustavovinagre.com)*

© 2022 THE AUTHORS. Published by Elsevier Inc. on behalf of the Arthroscopy Association of North America. This is an open access article under the CC BY-NC-ND license (<http://creativecommons.org/licenses/by-nc-nd/4.0/>).

2212-6287/22791

<https://doi.org/10.1016/j.eats.2022.08.043>

## Surgical Technique

The patient is positioned supine and spinal anesthesia is usually carried out. A single-leg holder is used, and the knee is flexed at 90°. A high-thigh tourniquet is placed on the operative limb inflated at 300 mm Hg.

A standard high anterolateral (AL) portal is made. The anteromedial portal is done under direct vision. A comprehensive diagnostic arthroscopy is performed, and associated injuries are addressed. The knee is held in a “figure-of-4” position for the opening of the lateral femorotibial space. In cases where there is not enough lateral compartment working space, the lateral pie-crusting technique can be used in 30° of flexion and constant knee varus force (Video 1). This technique improves the visualization and instrumentation of the lateral structures (Fig 1).

Release of the LCL may be necessary when a narrow femorotibial space is found, especially in complex procedures such as lateral meniscal repair or lateral allograft transplantation. The ideal candidate for this percutaneous release is a patient with a valgus knee pattern with no associated ligamentous lesions. Care should be taken in patients with varus alignment, lateral ligament laxity, or concomitant ipsilateral posterolateral ligamentous injuries. The advantages and risks of the LCL release are summarized in Table 1.

## Anatomic Landmarks

Bone references in the lateral side of the knee are the lateral epicondyle, Gerdy’s tubercle, and the fibular head. Laprade et al.<sup>15</sup> have measured the anatomic relation between these bony landmarks and the lateral knee stabilizers insertion site. Those surgical landmarks are palpated and marked on the skin. An anatomic dissection has been performed to improve the anatomic understanding of structures of the lateral side of the

knee and validate this technique in a cadaveric model (Figs 2-3).

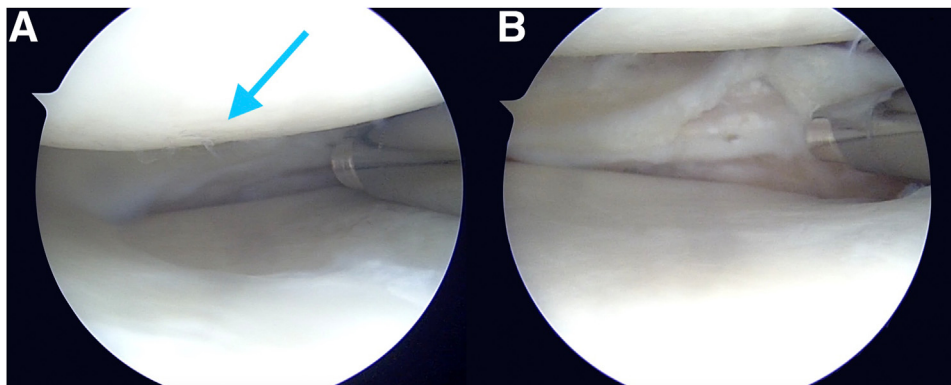
However, according to Kremen et al.,<sup>16</sup> there is a variability of the anatomy of lateral knee structures and a lack of reproducible radiographic criteria to identify these structures.

The primary stabilizers of the PLC are the LCL, the popliteus tendon (PLT), and the popliteofibular ligament (PFL). The femoral attachment of the LCL is 1.4 mm proximal and 3.1 mm posterior to the lateral epicondyle. The LCL inserts distally on the lateral aspect of the fibular head, slightly posterior to its anterior margin. The femoral insertion of the PLT is located 18.5 mm anterior and distal from the LCL attachment and courses posterodistally to insert into the posteromedial tibia through the popliteus muscle. The PLT insertion can be visualized arthroscopically through the lateral gutter and be used as a reference. The PFL originates at the musculotendinous junction of the popliteus and inserts in the medial aspect of the fibular styloid process with an anterior and a posterior division.<sup>15</sup>

Secondary stabilizers of the PLC include the anterolateral ligament (ALL), meniscomfemoral and meniscotibial ligaments, fabellofibular ligament, capsular arm of the short head of the biceps, biceps femoris tendon, and the iliotibial band. It is essential to avoid the common peroneal nerve that lies deep and inferior to the biceps femoris tendon and emerges posteriorly 1 to 2 cm proximal to the fibular head.<sup>8</sup>

## The Lateral Pie-Crusting Technique

The arthroscope is placed into the AL portal. A standard 18-gauge hypodermic needle is used for the release. Keeping a constant varus stress on the knee (with a single-leg holder) at 30° of flexion is recommended so that the LCL gets taut. The lateral



**Fig 1.** The patient is positioned supine and a leg holder is used to hold the right knee in a “figure-of-4” position. The arthroscope is placed in a standard anterolateral (AL) viewing portal of the right knee. (A) Before the lateral collateral ligament (LCL) pie-crusting: Incomplete meniscal visualization with probable iatrogenic cartilage damage with a 4.2-mm shaver (arrow). (B) After the LCL pie-crusting: Increased lateral joint space with safe and proper shaver utilization.

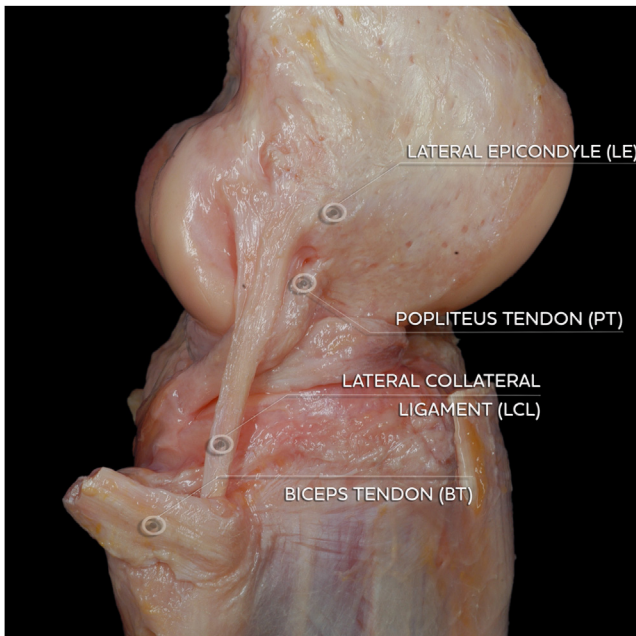
**Table 1.** Advantages and Risks With Lateral Pie-Crusting During Arthroscopic Lateral Femorotibial Compartment Surgery

| Advantages   | Risks  |
|--|--|
| <ul style="list-style-type: none"> <li>• Allow better visualization and identification of lateral femorotibial compartment pathology</li> <li>• Create a working space area without iatrogenic cartilage injury</li> <li>• Easier to perform complex surgical techniques (meniscal repair, meniscal root repair, meniscal transplantation, cartilage procedures, intra-articular fractures management)</li> <li>• Favorable clinical studies regarding the healing potential</li> <li>• Easy, safe, and reproducible technique</li> <li>• Lateral decompression in valgus knee patients</li> </ul> | <ul style="list-style-type: none"> <li>• Potential residual LCL laxity in varus knee patients</li> <li>• Iatrogenic injury to other PLC knee stabilizers</li> <li>• Iatrogenic injury to the peroneal nerve</li> </ul> |

LCL, lateral collateral ligament; PLC, posterolateral corner.

epicondyle is palpated, and the needle is inserted slightly posterior (3.1 mm) and proximal (1.4 mm) to this reference. With the arthroscope in the lateral gutter, the visible part of the PT also serves as a reference as the LCL insertion is located 15 to 20 mm proximal and slightly posterior. Generally, several fenestrations are needed to complete the lateral pie-crusting. A popping sound can be heard and felt when the LCL is released and joint aperture seen under direct arthroscopic visualization. Occasionally, a progressive lateral joint space opening is observed while lateral pie-crusting. An example of this technique in a cadaver model is shown in Fig 4.

Once the lateral pie-crusting is completed, there is no need to maintain maximal varus force to get a proper visualization. The pearls and pitfalls of this technique are summarized in Table 2.



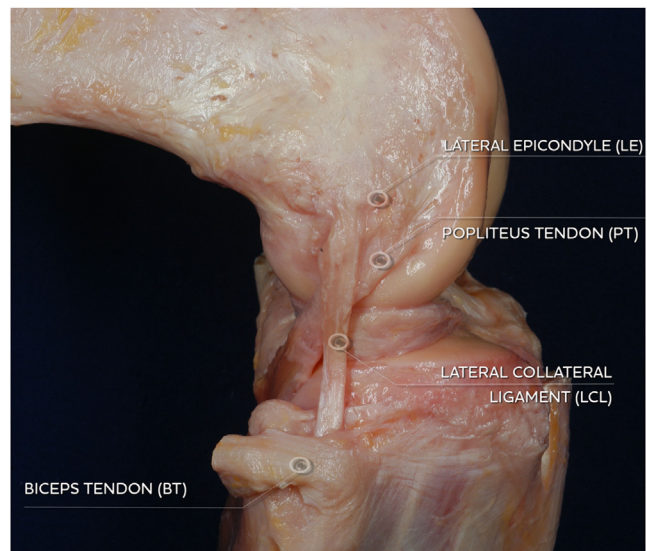
**Fig 2.** Anatomic cadaveric dissection of the lateral side of the knee (lateral view, right knee, extended position): lateral collateral ligament (LCL) and popliteus tendon (PT) and their relation to the lateral epicondyle (LE) and biceps tendon (BT).

## Postoperative Rehabilitation

Postoperatively, a knee brace in extension is recommended for 2 to 4 weeks, depending on the procedure. Knee flexion is limited to 90° through that time frame. After that period, patients can follow a standardized individual rehabilitation protocol without a brace. No varus laxity or instability has been noted either by clinical or physical examination of the patients 6 weeks postoperatively. However, a slower rehabilitation program should be considered.

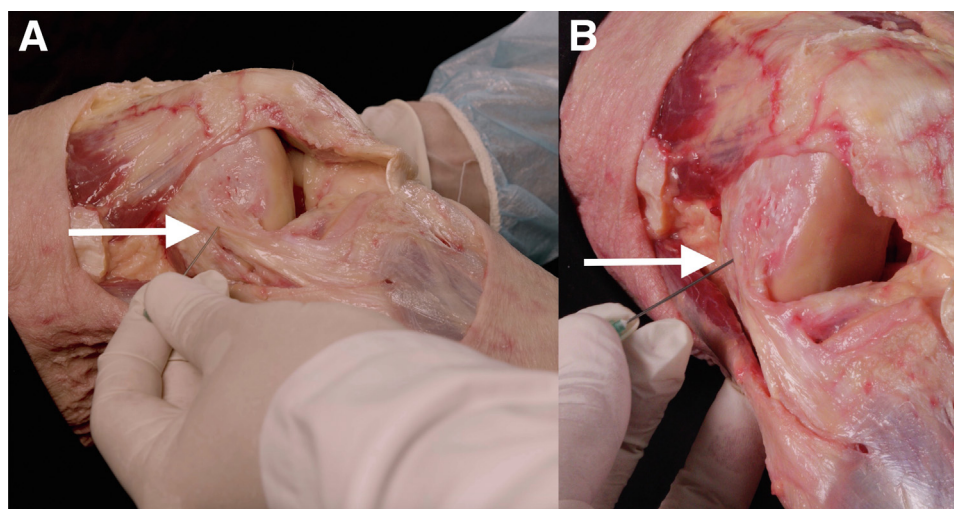
## Discussion

Adequate visualization and intervention are mandatory in knee arthroscopy surgery. Iatrogenic cartilage lesions and hidden injuries are common in narrow femorotibial spaces. Several articles have focused their attention on increasing the medial femorotibial area by releasing the MCL.<sup>4-6</sup> Medial pie-crusting is a common and efficient technique in increasing joint space without morbidity in the short or long term.<sup>17</sup> To our



**Fig 3.** Anatomic cadaveric dissection of the lateral femoral condyle and lateral collateral ligament (LCL) at 90° of flexion (lateral view, right knee). The popliteus tendon (PT) starts to enter the popliteal sulcus and gets tight.





**Fig 4.** Lateral pie-crusting technique in a cadaveric model. The right thigh is held at a 30° flexion angle while applying gentle and constant varus force. Lateral (A) and frontal (B) views show an 18-gauge needle pointing into the femoral attachment of the lateral collateral ligament (LCL) (arrows), which is slightly proximal and posterior to the lateral epicondyle (LE). The popliteus tendon (PT) femoral attachment is in the opposite direction— anterior and distal—18.5 mm from the LCL attachment. An arthroscopic view can also serve as a guide to avoiding PT injuries.

knowledge, there is no previous description for lateral femorotibial compartment controlled opening. This article represents a detailed Technical Note description of a percutaneous LCL “pie-crusting” technique.

It is generally accepted that the LCL is the primary restraint to varus stress. The most significant stabilizing varus effect of the LCL is observed at 30° of knee flexion.<sup>10</sup> In addition, Coobs et al.<sup>18</sup> have shown that sectioning the LCL increases external rotation in knee flexion and internal rotation through all ranges of flexion. However, they reported that the amount of tibia rotation controlled by LCL is relatively few. Wilson et al.<sup>19</sup> showed that MCL tensile strength is about twice that of the LCL, supporting previous reports that suggest all parts of the PLC are equally crucial for knee stability.<sup>20</sup> PFL with the rest of the connections of the popliteus complex (also known as arcuate ligament) plays an essential role in limiting external rotation, especially at the flexed position.<sup>21</sup> Meanwhile, internal rotation is controlled by the ALL, PLT, and the anterior cruciate ligament (ACL) as flexion increases.<sup>22</sup> LaPrade et al.<sup>23</sup> demonstrated that varus stability at 20° is also

dependent on the number of ligaments injured. They found that a gapping distance on varus stress radiograph increases by 2.71 mm when the LCL is torn and 6.55 mm when the PLT, PFL, and ACL are also damaged. Our anatomic dissection on a cadaveric model noted that PLT slackens at lower flexion angles, whereas LCL keeps tensioned at 30° of flexion. As described, the effect of a ligament function depends on the flexion angle and associated injuries. Therefore, isolated LCL release is crucial to reduce further instability after lateral pie-crusting. We advocate following a rigorous standardized technique to avoid PLT or PFL injury and exclude patients with concomitant ligament injuries. Through our dissections, we could verify that even if the popliteus tendon was punctured inadvertently, it was not injured, possibly due to its different ultrastructure from that of a ligament.

Over time, it has been argued that a torn LCL does not heal as well as a torn MCL.<sup>24</sup> Concerns are based on a convex lateral femoral condyle that articulates with a convex lateral tibial plateau, combined with lateral meniscus mobility. Animal models studied by LaPrade

**Table 2.** Pearls and Pitfalls of the Lateral Pie-Crusting Technique

| Pearls   | Pitfalls   |
|--|--|
| <ul style="list-style-type: none"> <li>• Palpate the LE and mark the puncture landmark site slightly proximal and posterior</li> <li>• Apply gentle and constant varus stress in 30° of flexion so that LCL can serve as a reference</li> <li>• Direct visualization under arthroscopy and snapping of the ligament confirm the correct lateral joint aperture</li> <li>• Popliteal sulcus can be noted and avoided in thinner patients</li> <li>• Several punctures are needed until a cracking sound and space widening occurs</li> <li>• Introduce the arthroscope in the lateral gutter to confirm PT integrity</li> </ul> | <ul style="list-style-type: none"> <li>• Release of the PT femoral attachment</li> <li>• Release LCL in patients with concomitant ipsilateral ligament injuries</li> </ul> |

LE, lateral epicondyle; LCL, lateral collateral ligament; PT, popliteus tendon.

et al.<sup>10</sup> and Griffith et al.<sup>25</sup> demonstrated residual instability 12 weeks after untreated grade III PLC lesions. There are a limited number of clinical studies on the lateral knee-healing capacity. In 1989, Kannus et al.<sup>9</sup> showed that patients with grades 2+ and 3+ (according to the American Medical Association classification) resulted in residual laxity when treated non-operatively.<sup>26</sup> In 1998, Krukhaug et al.<sup>27</sup> pointed in the same direction, but a subgroup of patients with 1+ varus and primarily mobilized was found to be completely stable at follow-up. As pointed out by LaPrade et al.<sup>23</sup> and Domnick et al.,<sup>28</sup> PLC classifications need to be reconsidered. Grade 1+ varus laxity (0 to 5 mm) could include LCL, PLT, and PFL injuries. The opinion of the authors of this study is that there is no published classification of isolated LCL injury because of its low frequency and its ability to heal. In 2009, Bushnell et al.<sup>29</sup> identified 9 elite-level patients with isolated high-grade LCL tears and found that nonoperative treatment achieved a more rapid return to play than surgery. A study by Temponi et al.<sup>12</sup> demonstrated by magnetic resonance imaging complete healing of isolated LCL tears when a hinged knee brace was used during the first 2 to 6 weeks.

Postoperative bracing may be a reasonable option after lateral pie-crusting. However, it is not mandatory after the MCL release.<sup>17</sup> According to our clinical observations, 2 to 4 weeks of bracing with knee extension may be enough to achieve knee stability after LCL release.

In conclusion, percutaneous LCL release during knee arthroscopy effectively improves lateral joint space and provides safer instrumentation and visualization. Lateral epicondyle landmarks and intraoperative arthroscopy are essential methods for safely performing a lateral pie-crusting. Current clinical evidence supports healing of isolated LCL injuries with no laxity at 6 weeks postoperatively. However, caution should be taken in patient selection until prospective outcomes studies are performed.

## References

- Garrett WE Jr, Swiontkowski MF, Weinstein JN, et al. American Board of Orthopaedic Surgery Practice of the Orthopaedic Surgeon: Part-II, certification examination case mix. *J Bone Joint Surg Am* 2006;88(3):660-667.
- Buckwalter JA. Articular cartilage injuries. *Clin Orthop Relat Res* 2002;(402):21-37.
- Compton J, Slattery M, Coleman M, Westermann R. Iatrogenic articular cartilage injury in arthroscopic hip and knee videos and the potential for cartilage cell death when simulated in a bovine model. *Arthroscopy* 2020;36(8):2114-2121.
- Bosch U. Percutaneous perforation of the posteromedial capsuloligamentous structures to avoid cartilaginous damage in narrow joints due to arthroscopic intervention at the medial meniscal posterior horn. *Oper Orthop Traumatol* 2006;18(5-6):481-484.
- Fakioglu O, Ozsoy MH, Ozdemir HM, Yigit H, Cavusoglu AT, Lobenhoffer P. Percutaneous medial collateral ligament release in arthroscopic medial meniscectomy in tight knees. *Knee Surg Sports Traumatol Arthrosc* 2013;21(7):1540-1545.
- Chernchujit B, Gajbhiye K, Wanaprasert N, Artha A. Percutaneous partial outside-in release of medial collateral ligament for arthroscopic medial meniscus surgery with tight medial compartment by finding a "magic point. *Arthrosc Techn* 2020;9(7):e935-e940.
- Claret G, Montañana J, Rios J, et al. The effect of percutaneous release of the medial collateral ligament in arthroscopic medial meniscectomy on functional outcome. *Knee* 2016;23(2):251-255.
- James EW, LaPrade CM, LaPrade RF. Anatomy and biomechanics of the lateral side of the knee and surgical implications. *Sports Med Arthrosc Rev* 2015;23(1):2-9.
- Kannus P. Nonoperative treatment of grade II and III sprains of the lateral ligament compartment of the knee. *Am J Sports Med* 1989;17(1):83-88.
- LaPrade RF, Wentorf FA, Crum JA. Assessment of healing of grade III posterolateral corner injuries: an in vivo model. *J Orthop Res* 2004;22(5):970-975.
- Bushnell BD, Bitting SS, Crain JM, Boublik M, Schlegel TF. Treatment of magnetic resonance imaging-documented isolated grade III lateral collateral ligament injuries in National Football League athletes. *Am J Sports Med* 2010;38(1):86-91.
- Temponi EF, Saithna A, de Carvalho LH, Teixeira BP, Sonnery-Cottet B. Nonoperative treatment for partial ruptures of the lateral collateral ligament occurring in combination with complete ruptures of the anterolateral ligament: A common injury pattern in Brazilian Jiu-Jitsu athletes with acute knee injury. *Orthop J Sports Med* 2019;7(1), 2325967118822450.
- Chernchujit B, Anilabol P, Malonzo VNF. Percutaneous lateral collateral ligament reconstruction. *Arthrosc Techn* 2020;9(10):e1577-e1580.
- Vermeijden HD, van der List JP, DiFelice GS. Primary repair of the lateral collateral ligament using additional suture augmentation. *Arthrosc Techn* 2020;9(8):e1073-e1077.
- LaPrade RF, Ly TV, Wentorf FA, Engebretsen L. The posterolateral attachments of the knee: A qualitative and quantitative morphologic analysis of the fibular collateral ligament, popliteus tendon, popliteofibular ligament, and lateral gastrocnemius tendon. *Am J Sports Med* 2003;31(6):854-860.
- Kremen TJ, Haggerty E, Chahla J, et al. Comparative analysis of sagittal-plane radiographic landmarks used to identify the femoral attachments of lateral knee structures. *Arthroscopy* 2020;36(11):2888-2896.
- Moran TE, Awowale JT, Werner BC, Fox MA, Miller MD. Associated morbidity after the percutaneous release of the medial collateral ligament for knee arthroscopy. *Arthroscopy* 2020 Mar;36(3):891-900.
- Coobs BR, LaPrade RF, Griffith CJ, Nelson BJ. Biomechanical analysis of an isolated fibular (lateral) collateral

- ligament reconstruction using an autogenous semitendinosus graft. *Am J Sports Med* 2007;35(9):1521-1527.
19. Wilson WT, Deakin AH, Payne AP, Picard F, Wearing SC. Comparative analysis of the structural properties of the collateral ligaments of the human knee. *J Orthop Sports Phys Ther* 2012;42(4):345-351.
  20. Covey DC. Injuries of the posterolateral corner of the knee. *J Bone Joint Surg Am* 2001;83(1):106-118.
  21. Thaunat M, Pioger C, Chatellard R, Conteduca J, Khaleel A, Sonnery-Cottet B. The arcuate ligament revisited: Role of the posterolateral structures in providing static stability in the knee joint. *Knee Surg Sports Traumatol Arthrosc* 2014;22(9):2121-2127.
  22. Parsons EM, Gee AO, Spiekerman C, Cavanagh PR. The biomechanical function of the anterolateral ligament of the knee. *Am J Sports Med* 2015;43(3):669-674.
  23. LaPrade RF, Heikes C, Bakker AJ, Jakobsen RB. The reproducibility and repeatability of varus stress radiographs in the assessment of isolated fibular collateral ligament and grade-III posterolateral knee injuries. An in vitro biomechanical study. *J Bone Joint Surg Am* 2008;90(10):2069-2076.
  24. Grawe B, Schroeder AJ, Kakazu R, Messer MS. Lateral collateral ligament injury about the knee: Anatomy, evaluation, and management. *J Am Acad Orthop Surg* 2018;26(6):e120-e127.
  25. Griffith CJ, Wijdicks CA, Goerke U, Michaeli S, Ellermann J, LaPrade RF. Outcomes of untreated posterolateral knee injuries: An in vivo canine model. *Knee Surg Sports Traumatol Arthrosc* 2011;19(7):1192-1197.
  26. American Medical Association. Committee on the Medical Aspects of Sports: Standard Nomenclature of Athletic Injuries. Prepared by the Subcommittee on Classification of Sports Injuries. Chicago, IL: American Medical Association, 1966.
  27. Krukhaug Y, Mølster A, Rodt A, Strand T. Lateral ligament injuries of the knee. *Knee Surg Sports Traumatol Arthrosc* 1998;6(1):21-25.
  28. Domnick C, Frosch KH, Raschke MJ, et al. Kinematics of different components of the posterolateral corner of the knee in the lateral collateral ligament-intact state: A human cadaveric study. *Arthroscopy* 2017;33(10):1821-1830.e1.
  29. Bushnell BD, Bitting SS, Crain JM, Boublik M, Schlegel TF. Treatment of magnetic resonance imaging-documented isolated grade III lateral collateral ligament injuries in National Football League athletes. *Am J Sports Med* 2010;38(1):86-91.